

Chapter 27

SMALLPOX

DAVID J. McCLAIN, M.D.*

INTRODUCTION

SMALLPOX AND BIOLOGICAL WARFARE

STRUCTURE AND BIOLOGY OF POXVIRUSES

PATHOGENESIS AND CLINICAL MANIFESTATIONS

DIAGNOSIS

MEDICAL MANAGEMENT

 Active Immunoprophylaxis

 Passive Immunoprophylaxis

 Chemoprophylaxis and Chemotherapy

SUMMARY

*Research Medical Officer, Division of Virology, U.S. Army Medical Research Institute of Infectious Diseases, Fort Detrick, Frederick, Maryland 21702-5011

INTRODUCTION

The poxviruses (of the family *Poxviridae*) are a family of large, enveloped deoxyribonucleic acid (DNA) viruses.¹ The most notorious poxvirus is variola, the causative agent of smallpox. Smallpox was an important cause of morbidity and mortality in the developing world until recent times. Since the host range of the variola virus is confined to humans, aggressive case identification and contact

vaccination were ultimately successful in controlling the disease. The last occurrence of endemic smallpox was in Somalia in 1977, and the last human cases were laboratory-acquired infections in 1978.² By 1980, the World Health Organization (WHO) General Assembly ratified the declaration of success made by the Global Commission for the Certification of Smallpox Eradication.

SMALLPOX AND BIOLOGICAL WARFARE

The concept of using variola virus in warfare is an old one. British colonial commanders considered distributing blankets from smallpox victims among Native Americans as a biological weapon.³⁻⁵ During the American Civil War, allegations were made about the use of smallpox as a biological weapon, although there subsequently proved to be no definite evidence for such.^{6,7} In the years leading up to and during World War II, the Japanese military explored weaponization of smallpox during the operations of Unit 731 in Mongolia and China.^{8,9}

Nevertheless, the actual potential of variola virus as a biological weapon remains controversial. Given the ease of administration and the availability of the vaccinia virus as a vaccine against smallpox,¹⁰ some have argued that smallpox would have limited biological warfare potential.¹¹ The Centers for Disease Control and Prevention (CDC), Atlanta, Georgia, presently maintains over 12 million doses of vaccinia vaccine in storage, and WHO has in storage enough vaccine to protect 200 to 300 million people.¹² On the other hand, the potency of stockpiled vaccine will gradually decline. The discontinuation of routine vaccination has rendered civilian and military populations more susceptible to a disease that is not only infectious by aerosol but also infamous for its devastating morbidity and mortality. WHO voiced concerns that smallpox "can easily be produced in large quantities in the laboratory and...freeze-dried and its virulence thus preserved for months or years."^{13(p69)}

Since 1983, there have existed two WHO-approved and -inspected repositories of variola virus: the CDC in the United States and Vector Laboratories in Russia. WHO continues to debate whether, given the completion of sequencing of several reference strains, all stocks of variola virus should be destroyed. Proponents of retaining these smallpox stocks argue that military or terrorist use of variola

virus as a weapon would readily be countered by rigorous case contact evaluation and vaccination. Furthermore, they reason that even if the repositories are eliminated, other potential sources of smallpox exist:

- Given the fact that viable variola virus could be recovered from scabs up to 13 years after collection,¹⁴ it is conceivable that cadavers preserved in permafrost¹⁵ or dry crypts¹⁶ could release the virus.
- Virus specimens from the smallpox-eradication campaign may remain unrecognized or unreported.
- Using the published sequence of variola and its significant homology with other *Orthopoxviruses*, a malevolent laboratory could theoretically engineer a recombinant virus exhibiting variola virus's virulence by starting with monkeypox virus.

Additionally, in the event that smallpox should re-emerge under one of the above scenarios, destroying the legitimate repositories of variola virus would hinder investigation into both (a) the mechanisms of viral pathogenesis, so as to effect countermeasures, and (b) detailed molecular epidemiology, so as to establish the precise phylogenetic relationship of an isolate to other known strains. Lastly, extinction of smallpox would disallow study of its unique proteins that interfere with host immune and regulatory functions (eg, homologues of epidermal growth factor, transforming growth factor, interleukin-1, interferon-, and zinc-finger protein).^{17,18}

Those who advocate eradication of the official variola virus repositories cite the possibility of accidental or intentional release of the virus as a threat to international public health; political instability

in Russia has reemphasized this concern. In addition, retention of these repositories might legitimize clandestine stockpiling or offensive biological warfare research on variola virus. Even if a virulent variola-like poxvirus could be engineered by an offensive biological warfare power, the lack of an animal model that accurately reflects human pathology¹⁹ would severely limit how it could be selected and tested. From the standpoint of understanding *Orthopoxvirus* biology, published sequence information on variola would be adequate to confirm the

identity of any smallpoxlike virus that might emerge in the future. Finally, further studies on poxvirus pathogenesis would be much more safely and successfully pursued using a poxvirus that does possess a good animal model, such as ectromelia (ie, mouse pox).²⁰ Despite the promise of variola virus's extinction as a biological entity, the prospect of surreptitious weaponization of smallpox remains vexing, and vaccination of military personnel could be seen as a defensive posture implying willingness to use variola virus as a weapon.²¹

STRUCTURE AND BIOLOGY OF POXVIRUSES

Possessing one of the largest genomes of any virus, an *Orthopoxvirus* consists of one piece of double-stranded DNA, which is cross-linked at each end.²² With their brick-shaped morphology, poxviruses have a biconcave core containing the DNA genome. The virus-encoded enzymes in the core are critical to transcription of the viral DNA. Genes encoding the nonessential functions important for virus virulence are arrayed near the ends of the genome; as would be expected, the greatest heterogeneity between poxviruses is at these genomic ends.^{23,24} There are 187 putative proteins identified from the sequencing of variola virus, of which 150 bear marked similarity to those of vaccinia virus. Encoded sequences include one for hemagglutinin, an envelope protein, and proteins that enhance growth in human cells. The other 37 proteins represent either variola-specific sequences, or *open reading frame* (ie, DNA sequences that are transcribed into ribonucleic acid [RNA], and hence are translated, via reading of the genetic code, into amino acid sequences) divergences from vaccinia counterparts.²⁵ These relatively small differences in vaccinia and variola virus proteins suggest that the variola-unique proteins act synergistically in bringing about the local and systemic manifestations for which smallpox is noted.

Most poxvirus virions appear to enter cells by pinocytosis, and then to uncoat within cytoplasmic vesicles. Poxvirus replication occurs in these discrete cytoplasmic inclusions, independent of the cell nucleus. Host biosynthetic processes are inhibited soon after poxvirus infection occurs. Virus transcription initiates almost immediately after entry, as DNA transcription is initiated by core enzymes while the genome is still in the core. Early gene products have to do with DNA synthesis, ensuring adequate levels of precursors for DNA synthesis and inhibition of host defense mechanisms.²⁶ This

is followed by release of DNA and subsequent synthesis of RNA and proteins.²⁷ It has been postulated²⁸ that viral DNA is transcribed and replicated from viral cores, or "deoxyribonucleoproteids." Although the virus encodes a DNA-dependent RNA polymerase, there is evidence²⁹ that subunits of cellular RNA polymerase II from the nucleus are somehow used in replication. Recombination events occur with high frequency during the replication process³⁰; these may also occur among different species of *Orthopoxviruses*.³¹

Viral DNA synthesis and intermediate regulatory genes are required for late gene expression.³² Proteins that are translated late include most of the structural proteins, as well as enzymes required for assembly of virion progeny. Maturation of virions is a complicated process entailing sequential assembly of poxvirus-specified macromolecules into particles. Unlike membranes of other enveloped viruses that are contiguous with host membranes, poxviruses assemble in the viroplasm into uniform, spherical, immature particles. This immature particle subsequently undergoes extensive conformational and biochemical changes before release, although most virions remain within the cell at the end of the growth cycle.³³ On release from the cell, the virion's outer (second) membrane fuses with the cell membrane; thus the released virion presents viral antigens not displayed in intracellular forms.³⁴ The sequence of events leading to release and dissemination of virions varies widely among different poxviruses.³⁵

Compared with other genera of vertebrate poxviruses (Table 27-1), members of the *Orthopoxvirus* genus (a) possess similar morphology and host range and (b) are antigenically related. Cross-reacting and species-specific neutralizing antigens have been identified by serum absorption and monoclonal antibody studies.^{36,37} Up to six antigens have

TABLE 27-1
CLASSIFICATION OF CHORDOPOXVIRIDAE
(VERTEBRATE POXVIRUSES)

Genera	Representative Species
<i>Orthopoxvirus</i>	Variola, vaccinia, monkeypox, cowpox, rabbitpox, raccoon pox, tatera pox, buffalopox, camelpox
<i>Avipoxvirus</i>	Fowlpox, canary pox
<i>Capripoxvirus</i>	Goatpox, sheeppox, lumpy skin disease
<i>Leporipoxvirus</i>	Myxoma, hare fibroma
<i>Parapoxvirus</i>	Orf (milker's nodule), pseudocowpox
<i>Suipoxvirus</i>	Swinepox
<i>Molluscipoxvirus</i>	Molluscum contagiosum
<i>Yatapoxvirus</i>	Tanapox, Yaba

been identified as neutralizing epitopes of *Orthopoxviruses*, one of these existing on naturally released but not on artificially released virions.³⁸

Undoubtedly, both cellular and humoral immune responses are important to recovery from smallpox. The inability of poxviruses to persist stably within the host cell accounts for their infections being relatively short-lived, without establishment of a latent infection. The importance of cellular immunity in recovery from infection has been demonstrated with other poxviruses,³⁹ and the same is generally assumed with variola. Vaccination experiences demonstrated the rare but terrible consequence of vaccinia necrosum in persons with defects of cellular immunity. Early presentation on the host cell membrane of virus-encoded proteins provides means for immune recognition.⁴⁰ It has been demonstrated that both antibody-dependent cellular cytotoxicity⁴¹ and heterogeneous cluster of differentiation (CD) 4+ cytotoxic T-lymphocyte clones⁴² are induced in response to vaccinia infection, and some immunodominant B-cell epitopes have been defined in both mice and vaccinated humans.⁴³ The relatively large size of poxvirus polypeptides facilitates their rec-

ognition and phagocytosis by the reticuloendothelial system. Viral antigens contained in the viral envelope are of preeminent importance with regard to protective antibody responses: envelope antigens were absent from virion suspensions used for inactivated smallpox vaccines, which proved to be ineffective.⁴⁴⁻⁴⁷

A naturally occurring relative of variola, monkeypox virus, is found in Africa, and the disease it causes, monkeypox, is clinically indistinguishable from smallpox, with the exception of notable enlargement of cervical and inguinal lymph nodes. The disease occurs mostly in monkeys from the tropical rain forests of central Africa, with sporadic transmission to humans. Some evidence supports the role of squirrels as the principal animal reservoir of the virus.⁴⁸ Over a span of 3 years, 331 cases of monkeypox disease in a population of 5 million have been reported.⁴⁹ Under natural conditions, the virus is transmitted by direct contact with an infected individual, fomites, and, occasionally by aerosol.

Concern has been raised whether the monkeypox virus could be weaponized and, if so, whether it would constitute a threat similar to that posed by variola virus. However, epidemiological evidence indicates that monkeypox virus has limited potential for person-to-person transmission, accounting for about 30% of the observed cases.⁵⁰ There is one report of its spread though four human generations.⁵¹ A stochastic model for interhuman spread of monkeypox indicates that it is very unlikely that the virus could sustain itself indefinitely in a community by interhuman transmission.⁵² The finite transmission potential of monkeypox prompted WHO to maintain active surveillance rather than a vaccination program in the endemic areas. Successful vaccinia virus immunization, as judged by the presence of a preexisting vaccination scar, affords approximately 85% protection against monkeypox.⁵³ Nevertheless, (a) the pathogenicity of monkeypox for humans, (b) the potential morbidity of an aerosolized monkeypox virus attack, and (c) the theoretical potential that genetic recombination could produce a modified animal poxvirus with enhanced virulence for humans have raised the specter that another poxvirus besides variola might constitute either a serious biowarfare threat or a reemergent public health problem.

PATHOGENESIS AND CLINICAL MANIFESTATIONS

Variola virus is highly stable and retains its infectivity for long periods outside the host.⁵⁴ It is infectious by aerosol,⁵⁵ but natural airborne spread

to other than close contacts is controversial.^{56,57} Approximately 30% of susceptible contacts became infected during the era of endemic smallpox,⁵⁸ and

the WHO eradication campaign was predicated on close person-to-person proximity being required for transmission to occur reliably. Nevertheless, variola virus's potential in low relative humidity for airborne dissemination was alarming in two hospital outbreaks.⁵⁹ Patients with smallpox were infectious from the time of onset of their eruptive exanthem, most commonly from days 3 through 6 after onset of fever. Infectivity was markedly enhanced if the patient manifested a cough. Indirect transmission via contaminated bedding or other fomites was infrequent.⁶⁰ Some close contacts harbored virus in their throats without developing disease, and hence might have served as a means of secondary transmission.⁶¹ There is no animal reservoir for variola virus, although monkeys are susceptible to infection.⁶²

On natural exposure to aerosolized virus, variola travels from the upper or the lower respiratory tract to regional lymph nodes, where it replicates and gives rise to viremia, which is followed soon thereafter by a rash.⁶³ The incubation period of smallpox averages 12 days, and contacts are quarantined for a minimum of 16 to 17 days following exposure. Following infection via the respiratory route and replication in local lymph nodes, variola virus disseminates systemically to other lymphoid tissues, spleen, liver, bone marrow, and lung. During this prodromal period, variola virus can be recovered from the blood, but the yield is much lower later in the illness. Clinical manifestations begin acutely with malaise, fever, rigors, vomiting, headache, and backache; 15% of patients develop delirium. Approximately 10% of light-skinned patients exhibit an erythematous rash during this phase.⁶⁴ Two to 3 days later, an enanthem appears concomitantly with a discrete rash about the face, hands, and forearms. Owing to the lack of a keratin layer on mucous membranes, lesions there shed infected epithelial cells and give rise to infectious oropharyngeal secretions in the first few days of the eruptive illness.⁶⁵ These respiratory secretions are the most important but not the sole means of virus transmission to contacts.

Following subsequent eruptions on the lower extremities, the rash spreads centrally during the next week to the trunk. Lesions quickly progress from macules to papules and eventually to pustular vesicles (Figure 27-1). Lesions are more abundant on the extremities and face, and this centrifugal distribution is an important diagnostic feature. In distinct contrast to the lesions seen in varicella, smallpox lesions on various segments of the body remain generally synchronous in their stage

of development. From 8 to 14 days after onset, the pustules form scabs, which leave depressed depigmented scars on healing. Although variola titers in the throat, conjunctiva, and urine diminish with time,⁶⁶ virus can readily be recovered from scabs throughout convalescence.⁶⁷ Therefore, patients should be isolated and considered infectious until all scabs separate.

For the past century, two distinct types of smallpox have been recognized. Variola major, the prototypical disease, was prevalent in Asia and parts of Africa. Variola minor, or alastrim, was distinguished by milder systemic toxicity and more diminutive pox lesions (Figure 27-2). Variola minor was found in Africa, South America, and Europe before the eradication of endemic disease, and caused 1% mortality in unvaccinated victims.

Three quarters of endemic cases of variola major fell into the classic, or ordinary, variety (see Figure 27-1). The fatality rate was 3% in vaccinated patients and 30% in unvaccinated. Other clinical forms of smallpox were associated with variola major, and it is likely that differences in both strain virulence and host response were responsible for these variations in clinical manifestations.⁶⁸ Flat-type smallpox, noted in 2% to 5% of patients, was typified by (a) severe systemic toxicity and (b) the slow evolution of flat, soft, focal skin lesions (Figure 27-3). This syndrome caused 66% mortality in vaccinated patients and 95% mortality in unvaccinated. Hemorrhagic-type smallpox, seen in fewer than 3% of patients, was heralded by the appearance of extensive petechiae (Figure 27-4), mucosal hemorrhage, and intense toxemia; death usually intervened before the development of typical pox lesions.⁶⁹

Bacterial superinfection of pox lesions was relatively uncommon except in the absence of proper hygiene and medical care. Arthritis and osteomyelitis developed late in the course of disease in about 1% to 2% of patients, more frequently occurred in children, and was often manifested as bilateral joint involvement, particularly of the elbows.⁷⁰ Viral inclusion bodies could be demonstrated in the joint effusion and bone marrow of the involved extremity. This complication reflected infection and inflammation of a joint followed by spread to contiguous bone metaphyses, and sometimes resulted in permanent joint deformity.⁷¹ Cough and bronchitis were occasionally reported as prominent manifestations of smallpox, with attendant implications for spread of contagion; however, pneumonia was unusual.⁷² Pulmonary edema occurred frequently in hemorrhagic- and flat-type smallpox. Orchitis was noted in approximately 0.1% of patients. Encephala-

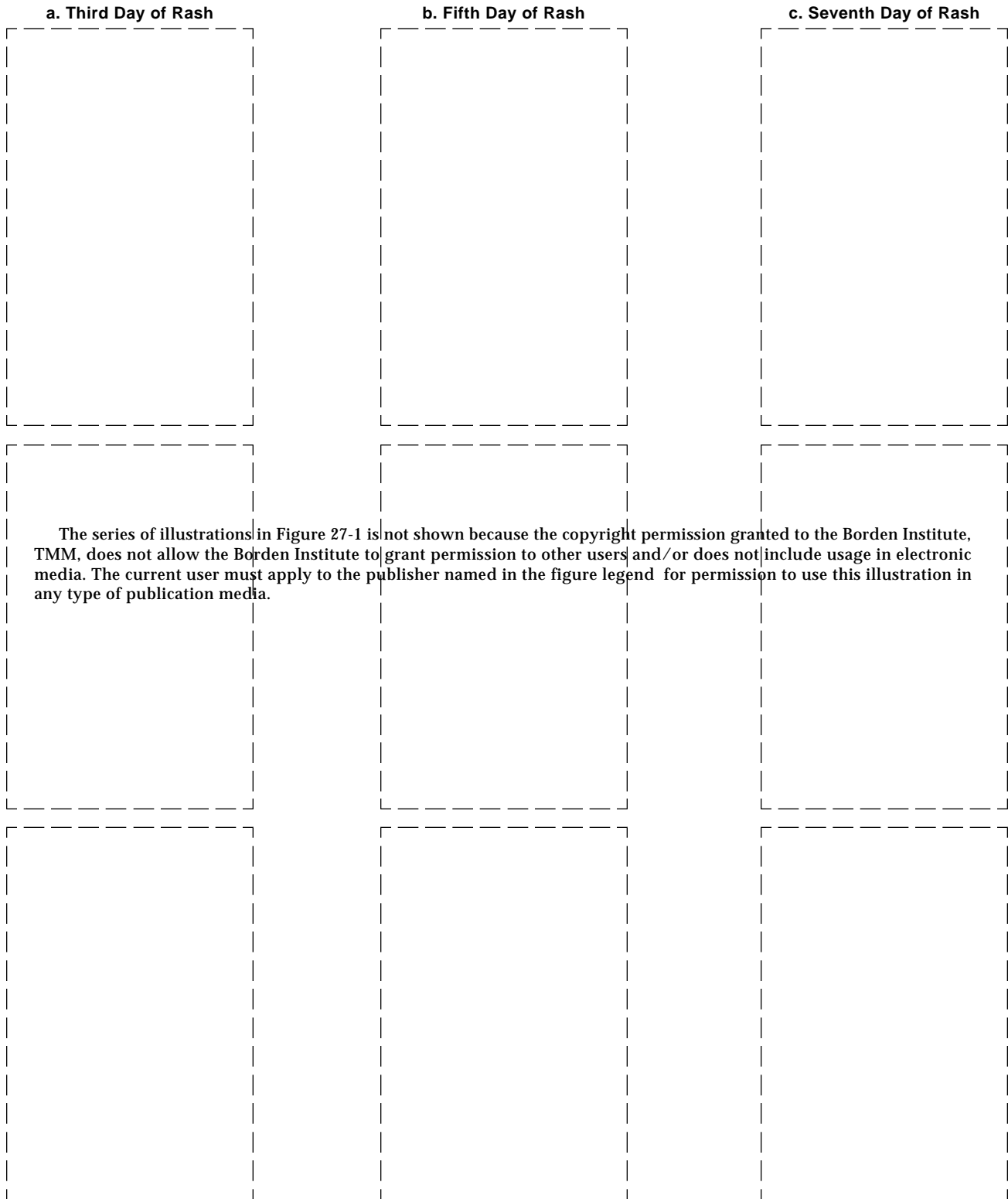


Fig. 27-1. This series of photographs illustrates the evolution of skin lesions in an unvaccinated infant with the classic form of variola major. (a) The third day of rash shows synchronous eruption of skin lesions; some are becoming vesiculated. (b) On the fifth day of rash, almost all papules are vesicular or pustular. (c) On the seventh day of rash, many lesions are umbilicated, and all lesions are in the same general stage of development. Photographs: Reprinted with permission from Fenner F, Henderson DA, Arita I, Jezek Z, Ladnyi ID. *Smallpox and Its Eradication*. Geneva, Switzerland: World Health Organization; 1988: 10–14. Photographs by I. Arita.

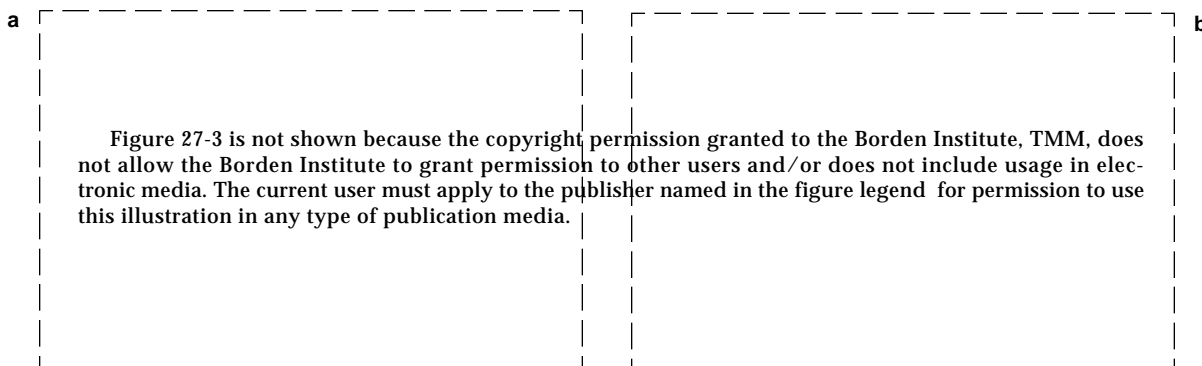
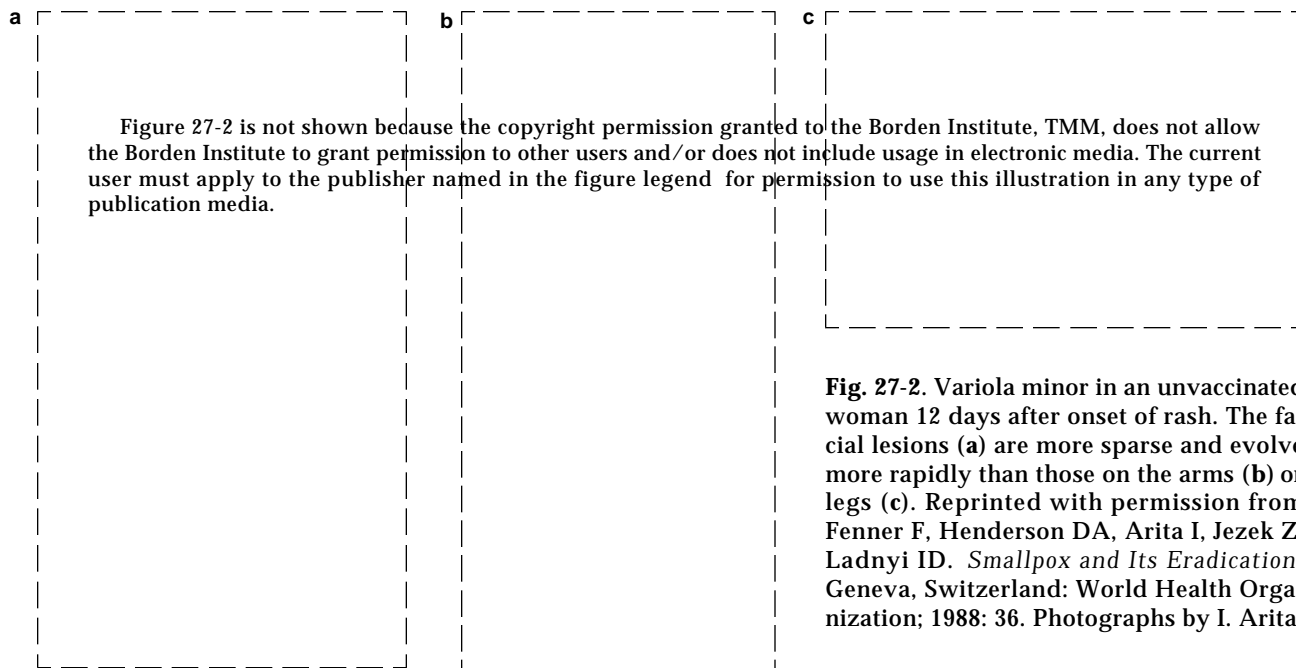


Fig. 27-3. Flat-type smallpox in an unvaccinated woman on the sixth day of rash. Extensive flat lesions (a and b) and systemic toxicity with fatal outcome were typical. Reprinted with permission from Fenner F, Henderson DA, Arita I, Jezek Z, Ladnyi ID. *Smallpox and Its Eradication*. Geneva, Switzerland: World Health Organization; 1988: 33. Photographs by F. Dekking.

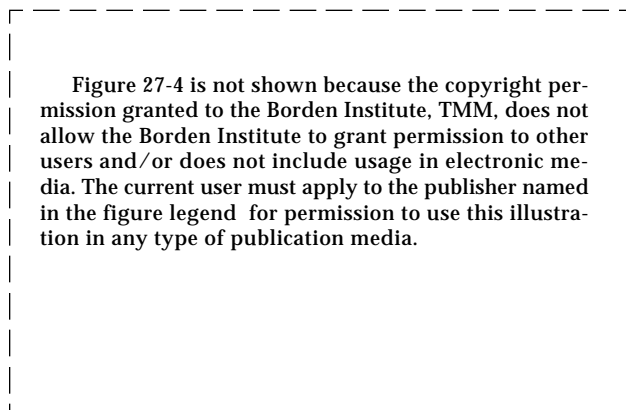


Fig. 27-4. Early hemorrhagic-type smallpox with cutaneous signs of hemorrhagic diathesis. Death usually intervened before the complete evolution of pox lesions. Reprinted with permission from Herrlich A, Mayr A, Munz E, Rodenwaldt E. *Die pocken; Erreger, Epidemiologie und klinisches Bild*. 2nd ed. Stuttgart, Germany: Thieme; 1967. In: Fenner F, Henderson DA, Arita I, Jezek Z, Ladnyi ID. *Smallpox and Its Eradication*. Geneva, Switzerland: World Health Organization; 1988: 35.

litis developed in 1 in 500 cases of variola major, compared with 1 in 2,000 cases of variola minor.⁷³ Keratitis and corneal ulcers were important complications of smallpox, progressing to blindness in slightly fewer than 1% of cases.⁷⁴ Disease during pregnancy precipitated high perinatal mortality, and congenital infection was also recognized.^{75,76}

Partial immunity from vaccination resulted in modified-type smallpox, in which sparse skin lesions evolved variably, often without pustules, and quickly, with crusting occurring as early as the seventh day of illness. Some fully immune individuals

would develop fever, sore throat, and conjunctivitis (called contact fever), on exposure to smallpox. This lasted several days, but did not give rise to the toxicity or minor skin lesions that signify variola sine eruptione.

Persons who recovered from smallpox possessed long-lasting immunity, although a second attack could occur in 1 in 1,000 persons after an intervening period of 15 to 20 years.⁷⁷ As discussed earlier, both humoral and cellular responses are important components of recovery from infection. Neutralizing antibodies peak 2 to 3 weeks following onset, and last longer than 5 years.⁷⁸

DIAGNOSIS

Given modern clinicians' lack of experience with smallpox, greater perspicacity is required to distinguish the forme fruste of this disease from other vesicular exanthems, such as those of chickenpox, erythema multiforme with bullae, or allergic contact dermatitis. Table 27-2 delineates some of the key features that differentiate variola from varicella (chickenpox virus). The failure to recognize relatively mild cases of smallpox in persons with partial immunity, who could unwittingly contribute to secondary spread by ambulating with their contagious exanthems undiagnosed, would present a particular problem to infection control. An additional threat to effective quarantine is the fact that exposed persons may shed virus from the oropharynx without ever manifesting disease. Therefore, quarantine and initiation of medical countermeasures should be followed

promptly by an accurate diagnosis so as to avert panic.

Rapid diagnostic tests may play an important role in discriminating smallpox from other diseases.^{79,80} The usual method of diagnosis is demonstration of characteristic virions on electron microscopy of vesicular scrapings. Under light microscopy, aggregations of variola virus particles, called Guarnieri bodies, correspond to B-type poxvirus inclusions (Figure 27-5). These cytoplasmic inclusions are hematoxylinophilic, stain reddish purple with Giemsa stain, and contain Feulgen-positive material.⁸¹ Another rapid but relatively insensitive test for Guarnieri bodies in vesicular scrapings is Gispens's modified silver stain, in which cytoplasmic inclusions appear black. The gel diffusion test, in which vesicular fluid from a pox lesion was incubated with vaccinia hyperimmune serum, con-

TABLE 27-2

DIFFERENTIATION BETWEEN SMALLPOX AND CHICKENPOX

	Variola	Varicella
Incubation Period	7-17 d	14-21 d
Prodrome	Fever and malaise for 2-4 d before onset of rash	Minimal to none
Pock Distribution	Centrifugal; usually on palms and soles	Centripetal; seldom on palms and soles
Pock Appearance	Vesicular—> pustular—> umbilicated—> scab	Vesicular on erythematous base—> pustular—> scab
Evolution of Pocks	Synchronous	Asynchronous
Scab Formation	10-14 d after onset of rash	4-7 d after onset of rash
Scab Separation	14-28 d after onset of rash	Within 14 d after onset of rash
Infectivity	From onset of enanthem until all scabs separate	From 1 d before rash until all vesicles scab

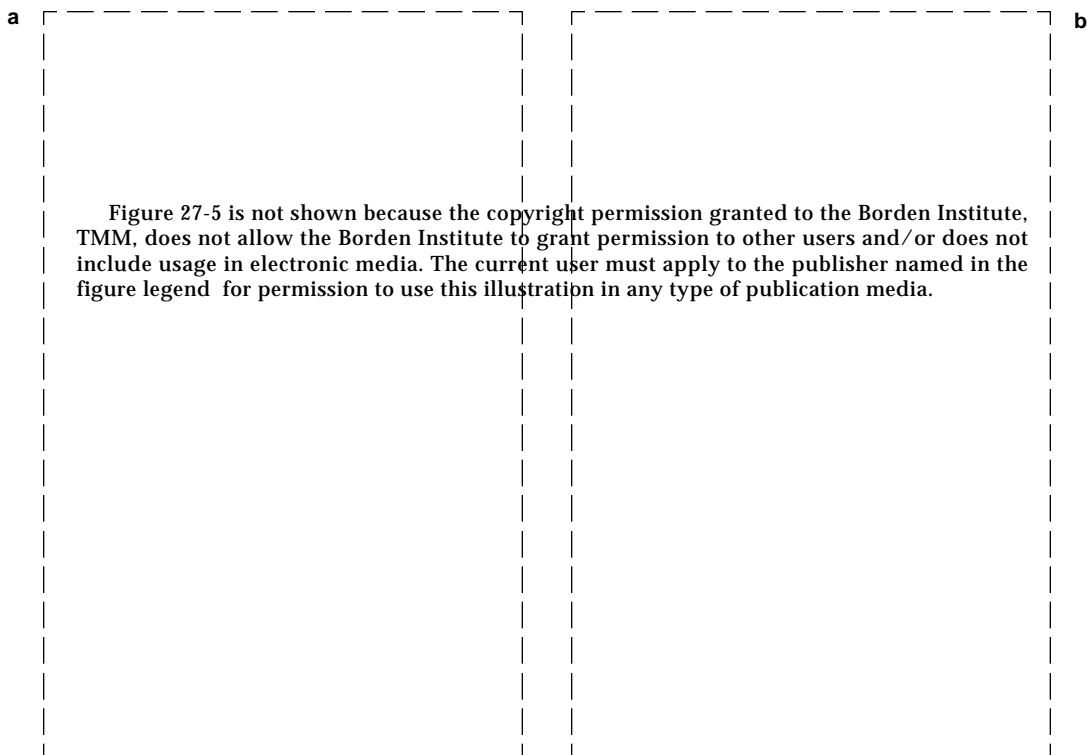


Fig. 27-5. Cytoplasmic inclusion bodies in cells infected with *Orthopoxviruses*. (a) B-type (pale-red, irregular) inclusion, or Guarnieri, bodies, and A-type (large eosinophilic, with halo) inclusion bodies in ectodermal cells of the chorioallantoic membrane, in a pock produced by cowpox virus. A number of nucleated erythrocytes are in the ectoderm and free in the mesoderm, and the surface of the pock is ulcerated. Hematoxylin-eosin stain. (b) This section of the skin of a patient with hemorrhagic-type smallpox shows Guarnieri bodies and free erythrocytes below an early vesicle. Hematoxylin-eosin stain. Photographs: Reprinted with permission from Fenner F, Henderson DA, Arita I, Jezek Z, Ladnyi ID. *Smallpox and Its Eradication*. Geneva, Switzerland: World Health Organization; 1988: 85.

stitutes a rapid and inexpensive method when microscopy is not available.⁸²

None of the above laboratory tests are capable of discriminating smallpox from vaccinia, monkeypox, or cowpox. Classically, this differentiation required isolation of the virus and characterization of its growth on chorioallantoic membrane. Pocks produced by smallpox are small and grayish white,

whereas those for vaccinia are larger and sometimes hemorrhagic. Variola minor exhibited greater temperature sensitivity on chorioallantoic membranes than did variola major.⁸³ The development of polymerase chain reaction diagnostic techniques promises a more accurate and less cumbersome method of discriminating among variola virus and other *Orthopoxviruses*.

MEDICAL MANAGEMENT

Medical personnel must be prepared to recognize a vesicular exanthem in possible biowarfare theaters as potentially smallpox, and to initiate appropriate countermeasures. Any confirmed case should be considered an international emergency, with an immediate report made not only to the chain of command but also to public health authorities. Strict quarantine with respiratory isolation should be applied for 17 days to *all* persons in direct contact with the index case or cases, especially the unvac-

inated. Immediate vaccination should also be undertaken for all personnel exposed to either weaponized variola or monkeypox virus or a clinical case of smallpox. Medical personnel should have a history of vaccination and should undergo immediate revaccination to ensure solid immunity.

Vaccination with a verified clinical *take* (ie, the local response to vaccination whereby a vesicle forms with surrounding erythema and induration) within the past 3 years is considered to render a

person immune to naturally occurring smallpox. However, given the difficulties and uncertainties under wartime conditions of verifying the adequacy of troops' prior vaccination, routine revaccination of all potentially exposed personnel would seem prudent if a significant prospect of smallpox exposure is believed to exist.

The key to control and eventual eradication of endemic smallpox was vigorous case identification, followed by quarantine and immunization of contacts. The fact that heterologous immunity provided by vaccination wanes with time is not fully appreciated: two thirds of smallpox victims in the 1960s had preexisting vaccination scars. Passive immunoprophylaxis using immune globulin was also examined, but, owing to the accepted efficacy of active immunization, the two methods were never compared against each other. No chemotherapy demonstrated efficacy against smallpox disease, but modest efficacy was shown in chemoprophylaxis. Present speculation regarding smallpox chemotherapy relies on *in vitro* data only.

Active Immunoprophylaxis

Vaccinia Vaccine

Early attempts to control smallpox included inoculation with material from smallpox lesions. This practice, known as variolization, caused severe cases of smallpox in about 1 in 200 inoculations.⁸⁴ In 1796, Jenner noted that milkmaids were free of the facial scars that marked most of the population during the smallpox epidemics of that time. The observation that they "cannot take smallpox" was attributed to the localized pox lesions that they developed on their hands. Jenner reasoned that infectious material (which he dubbed a "virus") from cowpox lesions provided protection from smallpox, and used it to vaccinate an 8-year-old boy. The boy later resisted variolation, demonstrating that an animal poxvirus that is not virulent for humans could be used as a potent vaccine against smallpox.⁸⁵

Vaccinia virus is another member of the orthopox genus of the Poxvirus family that possesses little pathogenicity for immunocompetent humans. Although the exact origin of vaccinia virus remains obscure,⁸⁶ it is related to cowpox, and strains of vaccinia virus became the vaccines of choice for the prevention of smallpox. The smallpox vaccines used in the eradication effort were prepared on a large scale by inoculating the shaved abdomens of calves, sheep, or water buffalo with seed stocks of vaccinia

virus, harvesting the infected exudative lymph from the inoculation sites, and bottling the product with phenol or brilliant green as a bacteriostatic agent.

Smallpox vaccines were most often administered by intradermal inoculation with a bifurcated needle, a process that became known as *scarification* because of the permanent scar that resulted. This method proved effective and successful when applied in the worldwide campaign to eradicate endemic smallpox, which primarily employed the New York City Board of Health (NYCBOH), EM-63, Lister, and Temple of Heaven strains. Although the Lister and Temple of Heaven vaccines putatively derived from transformation of variola into an attenuated virus, both animal studies⁸⁷ and restriction endonuclease analyses⁸⁸ indicate that they actually resulted from contamination with vaccinia during animal passages.

The human dose for vaccinia immunization is approximately 5 log₁₀ plaque-forming units given percutaneously. A vesicle typically appears at the vaccination site 5 to 7 days after the inoculation, with surrounding erythema and induration. The lesion forms a scab and gradually heals over the next 1 to 2 weeks.

Vaccination Complications

Side effects arising from vaccination are relatively uncommon but nevertheless finite. Low-grade fever and axillary lymphadenopathy may coincide with the culmination of the cutaneous pox lesion. The attendant erythema and induration of the vaccination vesicle is frequently misdiagnosed as bacterial superinfection. Formation of a scar on healing of the vesicle occurs routinely, and constitutes a permanent record of a take, or a successful primary vaccination.

One of the most thorough surveys of adverse reactions associated with vaccinia vaccines was conducted in the United States and published by the CDC in 1968,⁸⁹ and is summarized in Table 27-3. As a consequence of percutaneous inoculation, infectious vaccine virus is present in the local lesion. Consequently, inadvertent inoculation to other skin and mucous membrane sites (autoinoculation) or to other persons (secondary inoculation) is the most frequent complication of vaccinia intradermal vaccination.⁹⁰⁻⁹² Ocular vaccinia is a particularly troublesome problem resulting from secondary inoculation (Figure 27-6). Erythematous or urticarial rashes may occur approximately 10 days after primary vaccination and, rarely, Stevens-Johnson syndrome occurs. Generalized vaccinia is characterized

TABLE 27-3

RATES* OF REPORTED COMPLICATIONS ASSOCIATED WITH VACCINIA VACCINATIONS

Table 27-3 is not shown because the copyright permission granted to the Borden Institute, TMM, does not allow the Borden Institute to grant permission to other users and/or does not include usage in electronic media. The current user must apply to the publisher named in the figure legend for permission to use this illustration in any type of publication media.

*Cases per million vaccinations

†Includes patients with lesions that had bacterial superinfection, or that made the patient uncomfortable enough to consult a physician. Unusual complications included were a patient with fetal vaccinia, a patient with a melanoma developing in the vaccine scar, and a patient with monoarticular arthritis following vaccination.

Figure 27-6 is not shown because the copyright permission granted to the Borden Institute, TMM, does not allow the Borden Institute to grant permission to other users and/or does not include usage in electronic media. The current user must apply to the publisher named in the figure legend for permission to use this illustration in any type of publication media.

Fig. 27-6. Ocular vaccinia following inadvertent autoinoculation with vaccine. This complication can cause corneal scarring and hence visual impairment. Ocular vaccinia should be treated aggressively with a topical antiviral drug under close ophthalmological supervision. Reprinted with permission from Fenner F, Henderson DA, Arita I, Jezek Z, Ladnyi ID. *Smallpox and Its Eradication*. Geneva, Switzerland: World Health Organization; 1988: 298. Photograph by C. H. Kempe.

by a vesicular rash of varying extent occurring 6 to 9 days after primary vaccination; this complication is usually self-limited.

More severe complications of vaccinia vaccination include eczema vaccinatum, progressive vaccinia, and postvaccinial encephalitis. These complications are rare, but occur at least 10 times more often among primary vaccinees than among revaccinees. Eczema vaccinatum is a localized or systemic dissemination of vaccinia virus among persons who have eczema (Figure 27-7). Although usually mild and self-limited, this complication could be severe or even fatal in up to 10% of cases.

Progressive vaccinia (vaccinia necrosum) is a progressive necrosis in the area of vaccination, often with metastatic lesions (Figure 27-8). This complication occurred almost exclusively in persons with cellular immunodeficiency,⁹³ with a case fatality rate of higher than 75%.⁹⁴

Postvaccinial encephalitis most frequently affects primary vaccinees, with attendant mortality and serious neurologic morbidity of 25%.⁹⁵ Although the U.S. survey indicated the opposite, most countries reported a greater incidence of postvaccinial encephalitis from primary vaccination of older children and adults than of infants.⁹⁶

Vaccinia-immune globulin (VIG) is of value in the treatment of progressive vaccinia, eczema vaccinatum,⁹⁷ and perhaps ocular vaccinia (VIG is discussed below in the section titled Passive Immunoprophylaxis). Topical idoxuridine may benefit vaccinia keratitis.^{98,99}

Figure 27-7 is not shown because the copyright permission granted to the Borden Institute, TMM, does not allow the Borden Institute to grant permission to other users and/or does not include usage in electronic media. The current user must apply to the publisher named in the figure legend for permission to use this illustration in any type of publication media.

Fig. 27-7. Eczema vaccinatum. The widespread pox lesions on this patient's eczematous skin illustrate the severe illness that can occur in up to 10% of cases. Reprinted with permission from Fenner F, Henderson DA, Arita I, Jezek Z, Ladnyi ID. *Smallpox and Its Eradication*. Geneva, Switzerland: World Health Organization; 1988: 298. Photograph by I. D. Ladnyi.

Figure 27-8 is not shown because the copyright permission granted to the Borden Institute, TMM, does not allow the Borden Institute to grant permission to other users and/or does not include usage in electronic media. The current user must apply to the publisher named in the figure legend for permission to use this illustration in any type of publication media.

Fig. 27-8. Progressive vaccinia or vaccinia necrosum. As seen in this child, progressive viral replication at the inoculation site in an immunocompromised individual leads to inexorable local tissue destruction. Reprinted with permission from Fenner F, Henderson DA, Arita I, Jezek Z, Ladnyi ID. *Smallpox and Its Eradication*. Geneva, Switzerland: World Health Organization; 1988: 298. Photograph by C. H. Kempe.

Vaccination is contraindicated in the following conditions:

1. Immunosuppression, such as occurs with agammaglobulinemia, leukemia, lymphoma, generalized malignancy, or therapy with alkylating agents, antimetabolites, radiation, or large doses of corticosteroids. Such persons are at increased risk of progressive vaccinia.
2. Human immunodeficiency virus (HIV) infection. Severe vaccinia infections have been reported in persons immunosuppressed as a consequence of HIV disease.^{100,101}
3. Either history or evidence of eczema. Other exfoliative or extensive skin lesions (eg, atopic dermatitis, psoriasis, burns) may also place a person at increased risk for vaccination.
4. Current household, sexual, or other close physical contact with a person or persons possessing the condition or conditions listed in exclusion criteria 1 through 3, above.

5. Pregnancy. There have been rare instances of fetal vaccinia, usually following primary vaccination of pregnant women.^{102,103} This complication usually resulted in fetal demise or early postnatal mortality.

Despite the caveats listed above, most authorities state that, with the exception of significant impairment of systemic immunity, there are no absolute contraindications to *postexposure* vaccination of a person who experiences *bona fide* exposure to variola virus. However, in such circumstances, concomitant administration of VIG is recommended for pregnant women and individuals with eczema.

Indicators of Immunity

Vaccination with live vaccinia virus remains the principal defensive measure against smallpox, and against monkeypox, as well. Immunity to smallpox is gauged by the local response to vaccination (the *take*). However, not all vaccinations giving clinical takes will boost neutralizing antibody responses.¹⁰⁴ Evidence indicates that vaccinia provides protection against smallpox for at least 3 years after the vaccination.¹⁰⁵ With longer intervals between exposure and primary vaccination (or revaccination), protection is reduced. If vaccination is accomplished within a few days after exposure, then protection is also demonstrable,¹⁰⁶ approaching complete protection in those who have had their primary vaccination previously.¹⁰⁷ Postexposure vaccine failures were reported during trials in the smallpox era. Combined active immunization and passive immunization with VIG may provide improved postexposure prophylaxis. However, concomitant administration of VIG may attenuate the immune response to vaccination.¹⁰⁸

Protection following vaccinia immunization, like immunity following recovery from smallpox, has both a humoral and a cellular basis. One prospective study¹⁰⁹ of 146 contacts of patients with smallpox demonstrated that no contacts with significant titers of neutralizing antibody contracted the disease. However, 2 contacts with detectable titers still contracted the disease, and some persons with no neutralizing antibody were spared. In another investigation¹¹⁰ of 57 contacts of smallpox cases, all 6 who subsequently developed smallpox had neither a vaccination scar nor detectable neutralizing antibody. Therefore, data indicate that adequate serum titers of vaccinia-neutralizing antibody are usually sufficient, but not always necessary, for protection against variola virus. Neutralizing antibody

decreases during the first 3 years after vaccination, but titers remain sustained for several years following a second booster (ie, primary immunization and two revaccinations).^{111,112}

Contact Precautions

Vaccinia virus may be cultured from the site of primary vaccination for a time that begins at the development of a papule (2–5 d postvaccination) and lasts until the lesion has fully scabbed with no remaining vesicle (10–17 d postvaccination). During this period, infection-control measures are paramount in preventing secondary inoculation of the virus to other body sites or other persons. The lesion should be covered at all times with a dry dressing, and strict handwashing should be practiced after changing the dressing or touching the vaccination site. Semipermeable dressings predispose to accumulation of exudate beneath the dressing, with maceration and local secondary inoculation. Medical personnel should be excluded from caring for persons with active vaccinia lesions if the former are immunocompromised or possess chronic exfoliative skin lesions. Medical personnel who come in contact with contaminated materials (eg, dressings) from vaccinees are at relatively low risk of inadvertent inoculation, provided that they use appropriate infection control measures.¹¹³ The CDC has recommended that laboratory personnel who work with vaccinia or recombinant vaccinia viruses be vaccinated; this recommendation is controversial,¹¹⁴ however, and the risks of deliberate vaccination versus those of accidental inoculation must be weighed.

Vaccine Availability

The remaining vaccinia vaccine licensed in the United States (Dryvax, manufactured by Wyeth, Philadelphia, Pa.) is a live, infectious virus prepared from calf lymph. Like all smallpox vaccines that were marketed in the United States, it derived from the NYCBOH strain and contains 10⁸ plaque-forming units per milliliter. Current vaccinia vaccine stocks (> 12 million doses) are held by the CDC. It must be noted that the potency of several lots of this lyophilized vaccine has fallen. Pharmaceutical companies in the United States lack interest in manufacturing new lots of vaccine, owing to the absence of a profitable retail market, antiquation of calf-lymph production techniques and facilities, and the manufacturer's legal liability for vaccination complications.

Because of the declining potency of the existing smallpox vaccines and continued concerns about the prospect of the use of variola virus in biological warfare, a new vaccinia vaccine is in clinical testing by the U.S. Army Medical Research and Materiel Command, Fort Detrick, Frederick, Maryland. This vaccine was derived from a NYCBOH strain of vaccinia and then produced in human diploid lung fibroblast cell cultures. Unlike calf-lymph vaccines, this cell culture-derived vaccinia vaccine contains no adventitious agents.

Injectable Smallpox Vaccines

It has long been desired that vaccinia vaccine could be administered by injection; this route would preclude the complication of inadvertent inoculation of virus that was so prominent with the scarified calf-lymph vaccine. A potential disadvantage to subcutaneous or intramuscular inoculation would be the preclusion of a visible vesicle and scar as a means of assessing the take of a vaccination, which historically has been correlated to protection against smallpox. Plaque reduction neutralization antibody responses necessarily serve as the surrogate marker for an immune response that would protect against smallpox. Since the 1930s, at least eight strains of vaccinia virus were developed for parenteral administration. None were shown to be as immunogenic as standard calf-lymph strains administered by scarification, since they produced lower neutralizing antibody levels after primary and booster inoculations.¹¹⁵ Therefore, evidence indicates that subcutaneous, intramuscular, and intradermal vaccination without concomitant formation of a cutaneous pox lesion does not elicit as strong a serologic response as that obtained through scarification.^{116,117}

Recombinant Vaccinia Vaccines

Vaccinia virus has been proposed as a vaccine vector for foreign genes. This approach has been employed for expression of HIV proteins¹¹⁸ as well as other antigens. Vaccinia-naïve individuals inoculated with this vaccine developed antibodies not only to HIV-1¹¹⁹ but also to vaccinia. Therefore, it is possible that a future recombinant vaccinia vaccine containing a variety of viral or bacterial genes could serve multiple purposes, including immunity against smallpox. However, those vaccinia vectors engineered to be more attenuated¹²⁰ should be considered questionable in their ability to protect against variola virus. Neither would protection

against variola be expected from immunization with other vertebrate poxviruses, especially those of another genus such as *Avipox*.

Passive Immunoprophylaxis

Evidence indicates that vaccinia-immune globulin is of value in postexposure prophylaxis of smallpox when given (a) within the first week following exposure and (b) concurrently with vaccination.¹²¹ However, the prophylactic use of VIG should be carefully weighed vis-à-vis the risk of attenuating the immune response to booster vaccination.

VIG is available in the United States from the Drug Service of the CDC; the U.S. Army maintains a supply for its own use. The dose for prophylaxis or treatment is 0.6 mL/kg, administered intramuscularly. Administration immediately after or within the first 24 hours of exposure would provide the highest level of protection, especially in unvaccinated persons. VIG is prepared from the plasma of repeatedly vaccinated persons. Development of humanized monoclonal antibodies against neutralizing epitopes that are conserved between vaccinia and variola viruses is a promising alternative to this older, cumbersome, and expensive method of VIG production.

Chemoprophylaxis and Chemotherapy

During the 1960s, methisazone (Marboran, no longer available; then manufactured by Burroughs Wellcome, Research Triangle Park, N. C.; also called 1-methylisatin 3'-thiosemicarbazone) received extensive attention as an antiviral chemotherapy for variola virus infections. Although some clinical studies found only a trend toward decreased attack rates,^{122,123} most evidence suggested that methisazone decreased both morbidity and mortality when administered *prophylactically* to susceptible contacts of patients with smallpox.¹²⁴⁻¹²⁷ Although a variety of dosages and schedules were tested, most experience was with 3 g administered orally, at least two doses given 8 hours apart. Gastrointestinal intolerance (nausea and vomiting) significantly hampered both medication administration and patient compliance.

Although clinical trials^{128,129} showed no *therapeutic* efficacy of thiosemicarbazones against smallpox, anecdotal reports^{130,131} suggest some usefulness of methisazone in treating progressive vaccinia.

Other antiviral compounds, such as rifampin¹³² and S-adenosylhomocysteine hydrolase inhibitors,¹³³⁻¹³⁵ have activity against vaccinia, and hence

may be useful in the prophylaxis or treatment of smallpox. However, it should be noted that despite their in vitro efficacy against vaccinia, neither cy-

tosine arabinoside (Ara-C)¹³⁶ nor adenine arabinoside (Ara-A)¹³⁷ demonstrated benefit in treatment of smallpox in small clinical studies.

SUMMARY

Despite the eradication of naturally occurring smallpox and the availability of a vaccine, the potential weaponization of variola virus continues to pose a military threat. This threat can be attributed to the aerosol infectivity of the virus, the relative ease of large-scale production, and an increasingly *Orthopoxvirus*-naïve human populace.

Although the fully developed cutaneous eruption of smallpox is unique, earlier stages of the rash could be mistaken for varicella. Secondary spread

of infection constitutes a nosocomial hazard from the time of onset of a smallpox patient's enanthem until scabs have separated. Quarantine with respiratory isolation should be applied to secondary contacts for 17 days after the exposure.

Vaccinia vaccine remains the preeminent countermeasure for preexposure prophylaxis against smallpox. Vaccinia vaccination, vaccinia immune globulin, and methisazone each possess some efficacy in postexposure prophylaxis.

REFERENCES

1. Fenner F, Wittek R, Dumbell KR. *The Orthopoxviruses*. Orlando, Fla: Academic Press; 1989.
2. Her Majesty's Stationery Office. *Report of the Investigations Into the Cause of the 1978 Birmingham Smallpox Occurrence*. London, England: HMSO; 1980.
3. Heagerty JJ. *Four Centuries of Medical History in Canada*. Vol 1. Toronto, Ont, Canada: MacMillan; 1928.
4. Parkman F. *The Conspiracy of Pontiac*. Vol 2. Boston, Mass: Little, Brown; 1969: 44–46.
5. Stearn EW, Stearn AE. *The Effects of Smallpox on the Destiny of the Amerindians*. Boston, Mass: Bruce Humphries; 1945: 44–45.
6. Kean RGH. *Inside the Confederate Government*. New York, NY: Oxford University Press; 1957: 89.
7. Steiner PE. *Disease in the Civil War: Natural Biological Warfare in 1861–1865*. Springfield, Ill: Charles C Thomas; 1968: 42–43.
8. Harris R, Paxman J. *A Higher Form of Killing*. New York, NY: Hill and Wang; 1982: 76–79, 153.
9. Williams P, Wallace D. *Unit 731: Japan's Secret Biological Warfare in World War II*. New York, NY: Free Press; 1989: 28, 213.
10. Henderson DA. The eradication of smallpox. In: Last JM, ed. *Maxcy-Rosenau Public Health and Preventive Medicine*. 12th ed. Norwalk, Conn: Appleton-Century-Crofts; 1986: 129–138.
11. Fenner F, Henderson DA, Arita I, Jezek Z, Ladnyi ID. Potential sources for a return of smallpox. In: *Smallpox and Its Eradication*. Geneva, Switzerland: World Health Organization; 1988: Chap 30: 1341.
12. Capps L, Vermund SH, Johnsen C. Smallpox and biological warfare: The case for abandoning vaccination of military personnel. *Am J Public Health*. 1986;76(10):1229–1231.
13. World Health Organization. Health aspects of chemical and biological weapons: Report of a WHO group of consultants. Geneva, Switzerland: WHO; 1970: 69–70.
14. Wolff HL, Croon JAB. Survival of smallpox virus (*variola minor*) in natural circumstances. *Bull WHO*. 1968;38:492–493.

15. Zuckerman AJ. Paleontology of smallpox. *Lancet*. 1984;2:1454.
16. Baxter PJ, Brazier AM, Young SEJ. Is smallpox a hazard in church crypts? *Br J Industr Med*. 1988;45:359–360.
17. Joklik WK, Moss B, Fields BN, Bishop DHL, Sandakhchiev LS. Why the smallpox virus stocks should not be destroyed. *Science*. 1993;262:1225–1226.
18. Buller RM, Palumbo GJ. Poxvirus pathogenesis. *Microbiol Rev*. 1991;55:80.
19. Hahon N, Wilson BJ. Pathogenesis of variola in *Macaca irus* monkeys. *Am J Hyg*. 1960;71:69–80.
20. Mahy BWJ, Almond JW, Berns KI, et al. The remaining stocks of smallpox virus should be destroyed. *Science*. 1993;262:1223–1224.
21. Capps L, Vermund SH, Johnsen C. Smallpox and biological warfare: The case for abandoning vaccination of military personnel. *Am J Publ Health*. 1986;76:1229–1231.
22. Geshelin P, Berns KI. Characterization and localization of the naturally occurring cross-links in vaccinia virus DNA. *J Mol Biol*. 1974;88:785–796.
23. Müller HK, Wittek KR, Schaffner W, Schümperli D, Menna A, Wyler R. Comparison of five poxvirus genomes by analysis with restriction endonucleases *HindIII*, *BamI* and *EcoRI*. *J Gen Virol*. 1977;38:135–147.
24. Mackett M, Archard LC. Conservation and variation in *Orthopoxvirus* genome structure. *J Gen Virol*. 1979;45:683–701.
25. Massung RF, Esposito JJ, Liu LI, et al. Potential virulence determinants in terminal regions of variola smallpox virus genome. *Nature*. 1993;366:748–750.
26. Moss B. Regulation of vaccinia virus transcription. *Annu Rev Biochem*. 1990;59:661–668.
27. Kates JR, McAuslan BR. Messenger RNA synthesis by a “coated” viral genome. *Proc Natl Acad Sci USA*. 1967;57:314–320.
28. Zaslavsky V. Uncoating of vaccinia virus. *J Virol*. 1985;55:352–356.
29. Moyer RW. The role of the host cell nucleus in vaccinia virus morphogenesis. *Virus Res*. 1987;8:173–191.
30. Merchilinsky M. Intramolecular homologous recombination in cells infected with temperature-sensitive mutants of vaccinia virus. *J Virol*. 1989;63:2030–2035.
31. Bedson HS, Dumbell KR. Hybrids derived from the viruses of variola major and cowpox. *J Hygiene*. 1964;62:147–148.
32. Keck JC, Baldick CJ, Moss B. Role of DNA replication in vaccinia virus gene expression: A naked template is required for transcription of three late *trans*-activator genes. *Cell*. 1990;61:80–89.
33. Moss B. Poxviridae and their replication. In: Fields BN, Knipe DM, eds. *Virology*. 2nd ed. New York, NY: Raven Press; 1990: 2079–2111.
34. Dales S, Pogo BGT. Biology of poxviruses. *Virol Monogr*. 1981;18:1.
35. Ichihashi Y, Matsumoto S, Dales S. Biogenesis of poxviruses: Role of A-type inclusions and host cell membranes in virus dissemination. *Virology*. 1977;101:50–60.
36. Baxby D. The surface antigens of *Orthopoxviruses* detected by cross-neutralization tests on cross-absorbed antisera. *J Gen Virol*. 1982;58:251–262.

37. Kitamoto N, Tanimoto S, Hiroi K, et al. Monoclonal antibodies to cowpox virus: Polypeptide analysis of several major antigens. *J Gen Virol*. 1987;68:239–246.
38. Boulter EA, Appleyard G. Differences between extracellular and intracellular forms of poxvirus and other implications. *Prog Med Virol*. 1973;16:86–108.
39. Cole GA, Blanden RV. Immunology of poxviruses. In: Nahmias AJ, O'Reilly RJ, eds. *Immunology of Human Infection. Part 2: Viruses and Parasites; Immunodiagnosis in Prevention of Infectious Diseases. Vol 9. In: Comprehensive Immunology*. New York, NY: Plenum Press; 1982: 1–19.
40. Mallon VR, Holowczak JA. Vaccinia virus antigens on the plasma membrane of infected cells, I: Viral antigens transferred from infecting virus particles and synthesized after infection. *Virology*. 1985;141:201–220.
41. Perrin LH, Zinkernagel RM, Oldstone MB. Immune response in humans after vaccination with vaccinia virus: Generation of a virus-specific cytotoxic activity by human peripheral lymphocytes. *J Exp Med*. 1977;146:949–969.
42. Littau RA, Takeda A, Cruz J, Ennis FA. Vaccinia virus-specific human CD4+ cytotoxic T-lymphocyte clones. *J Virol*. 1992;66(4):2274–2280.
43. Demkowicz WE, Maa JS, Esteban M. Identification and characterization of vaccinia virus genes encoding proteins that are highly antigenic in animals and are immunodominant in vaccinated humans. *J Virol*. 1992;66(1):386–398.
44. Payne L. Significance of extracellular enveloped virus in the in vitro and in vivo dissemination of vaccinia. *J Gen Virol*. 1980;50:89–100.
45. RamanaRao AV. The immunogenicity of inactivated vaccinia virus. *J Path Bact*. 1962;84:367–377.
46. Kaplan C, McLean D, Vallet L. A note on the immunogenicity of ultraviolet irradiated vaccinia virus in man. *J Hygiene* 1962;60:79–83.
47. Kaplan C, Benson PF, Butler NR. Immunogenicity of ultraviolet-irradiated, non-infectious, vaccinia-virus vaccine in infants and young children. *Lancet*. 1965;1:573–574.
48. Khodakevich L, Szczeniowski M, Manbu-ma-Disu, et al. The role of squirrels in sustaining monkeypox virus transmission. *Trop Geogr Med*. 1987;39:115–122.
49. Baxby D. Human poxvirus infection after the eradication of smallpox. *Epidemiol Infect*. 1988;100:321–334.
50. Jezek Z, Fenner F. Human monkeypox. *Viol Monogr*. 1988;17:93–95.
51. Jezek Z, Arita I, Mutombo M, Dunn C, Nakano JH, Szczeniowski M. Four generations of probable person-to-person transmission of human monkeypox. *Am J Epidemiol*. 1986;123:1004–1012.
52. Jezek Z, Grab B, Dixon H. Stochastic model for the interhuman spread of monkeypox. *Am J Epidemiol*. 1987;126:1082–1089.
53. Fine PEM, Jezek Z, Grab B, Dixon J. The transmission potential of monkeypox virus in human populations. *Int J Epidemiol*. 1988;17(3):643–650.
54. Huq F. Effect of temperature and relative humidity on variola virus in crusts. *Bull WHO*. 1976;54:710–712.
55. Noble J, Rich JA. Transmission of smallpox by contact and by aerosol routes in *Macaca irus*. *Bull WHO*. 1969;40:279–286.
56. Meikeljohn G, Kempe CH, Downie AW, Berge TO, St. Vincent L, Rao AR. Air sampling to recover variola virus in the environment of a smallpox hospital. *Bull WHO*. 1961;25:63–67.

57. Downie AW, Meiklejohn M, St Vincent L, Rao AR, Sundara Babu BV, Kempe CH. The recovery of smallpox from patients and their environment in a smallpox hospital. *Bull WHO*. 1965;33:615–622.
58. Foege WH, Millar JD, Henderson DA. Smallpox eradication in West and Central Africa. *Bull WHO*. 1975;52:209–222.
59. Wehrle PF, Posch J, Richter KH, Henderson DA. An airborne outbreak of smallpox in a German hospital and its significance with respect to other recent outbreaks in Europe. *Bull WHO*. 1970;43:669–679.
60. MacCallum FO, McDonald JR. Survival of variola virus in raw cotton. *Bull WHO*. 1957;16:247–254.
61. Sarkar JK, Mitra AC, Mukherjee MK, De SK. Virus excretion in smallpox, II: Excretion in the throats of household contacts. *Bull WHO* 1973;48:523–527.
62. Horgan ES, Ali Haseeb M. Cross immunity experiments in monkey between variola, alastrim and vaccinia. *J Hygiene*. 1939;39:615–637.
63. Hahon N. Smallpox and related poxvirus infections in the simian host. *Bact Rev*. 1961;25:459–476.
64. Ricketts TF. *The Diagnosis of Smallpox*. London, England: Cassell; 1908.
65. Downie AW, St. Vincent L, Meiklejohn G, et al. Studies on the virus content of mouth washings in the acute phase of smallpox. *Bull WHO*. 1961;25:49–53.
66. Sarkar JK, Mitra AC, Mukherjee MK, De SK, Mazumdar DG. Virus excretion in smallpox. *Bull WHO*. 1973;48:517–522.
67. Mitra AC, Sarkar JK, Mukherjee MK. Virus content of smallpox scabs. *Bull WHO*. 1974;51:106–107.
68. Sarkar JK, Mitra AC. Virulence of variola virus isolated from smallpox cases of varying severity. *Indian J Med Res*. 1967;55(1):13–20.
69. Downie AW, Fedson DS, St. Vincent L, Rao AR, Kempe CH. Haemorrhagic smallpox. *J Hyg*. 1969;67:619–629.
70. Gupta SK, Srivasta TP. Roentgen features of skeletal involvement in smallpox. *Aust Radiol*. 1973;17:205–211.
71. Cockshott P, MacGregor M. Osteomyelitis variolosa. *Q J Med*. 1958;27:369–387.
72. Fenner F, Henderson DA, Arita I, Jezek Z, Ladnyi ID. The clinical features of smallpox. In: *Smallpox and Its Eradication*. Geneva, Switzerland: World Health Organization; 1988: Chap 1: 48.
73. Marsden JP. Variola minor: A personal analysis of 13,686 cases. *Bulletin of Hygiene*. 1948;23:735–746.
74. Hughes K. *Fatality, Facial Scarring and Blindness From Smallpox in Bangladesh*. Geneva, Switzerland: 1978. WHO/SE/78.101.
75. Marsden JP, Greenfield CRM. Inherited smallpox. *Arch Dis Child*. 1934;9:309–314.
76. Ribeiro AM, de Salles-Gomes LF, Schmidt BJ, Kopelman BI, Pimenta de Campos E, Carvalho AA. Fetal variola: Report of two cases. *Helvetica Paediatrica Acta*. 1965;20:369–373.
77. Rao AR. *Smallpox*. Bombay, India: Kothari Book Depot; 1972.
78. Downie AW, St. Vincent L, Goldstein L, Rao AR, Kempe CH. Antibody response in non-haemorrhagic smallpox patients. *J Hygiene*. 1969;67:609–618.
79. World Health Organization. *Guide to the Laboratory Diagnosis of Smallpox for Smallpox Eradication Programs*. Geneva, Switzerland: World Health Organization; 1969.

80. Nakano JH. Evaluation of virological laboratory methods in smallpox diagnosis. *Bull WHO*. 1973;48:529–534.
81. Kato S, Takahashi, Kameyama, Kamahora J. A study on the morphological and cyto-immunological relationship between the inclusions of variola, cowpox, rabbitpox, vaccinia (variola origin) and vaccinia IHD and consideration of the term “Guarnieri body.” *Biken J*. 1959;2:353–363.
82. Mitra AC, Sarkar SK, Mukherjee MK, Chakravarty MS. Evaluation of the precipitation-in-gel reaction in the diagnosis of smallpox. *Bull WHO*. 1973;49:555–558.
83. Dumbell KR, Bedson HS, Rossier E. The laboratory differentiation between variola major and variola minor. *Bull WHO*. 1961;25:73–78.
84. Baxby D. *Jenner’s Smallpox Vaccine*. London, England: Heinemann Educational Books; 1981.
85. Bloch H. Edward Jenner: The history and effects of smallpox, inoculation, and vaccination. *Am J Dis Child*. 1993;147:772–774.
86. Baxby D. Poxviruses. In: Parker MT, Collier LH, eds. *Topley and Wilson’s Principles of Bacteriology, Virology and Immunity*. 8th ed, vol 4. London, England: Arnold; 1990: 559–571.
87. Herrlich A, Mayr A, Mahnel H, Munz E. Experimental studies on transformation of the variola virus into the vaccinia virus. *Archiv für die gesamte Virusforschung*. 1963;12:579–599.
88. Baxby D. Vaccinia virus. In: Quinnan GV, ed. *Vaccinia Viruses as Vectors for Vaccine Antigens*. New York, NY: Elsevier; 1985: 11–23.
89. Lane JM, Ruben FL, Neff JM, Millar JD. Complications of smallpox vaccination, 1968: Results of ten statewide surveys. *J Infect Dis*. 1970;122:303–309.
90. Centers for Disease Control. Contact spread of vaccinia from a recently vaccinated Marine—Louisiana. *MMWR*. 1984;33(3):37–38.
91. Centers for Disease Control. Contact spread of vaccinia from a National Guard vaccinee. *MMWR*. 1985;34(13):182–183.
92. Lane JM, Reuben FL, Neff JM, et al. Complications of smallpox vaccination, 1968: National surveillance in the United States. *New Engl J Med*. 1969;281:1201–1207.
93. Fulginiti VA, Kempe CH, Hathaway WE, et al. Progressive vaccinia in immunologically deficient individuals. *Birth Defects*. 1968;4:129–145.
94. Freed ER, Richard JD, Escobar MR. Vaccinia necrosum and its relationship to impaired immunologic responsiveness. *Am J Med*. 1972;52:411–420.
95. Goldstein JA, Neff JM, Lane JM, Koplan JP. Smallpox vaccination reactions, prophylaxis and therapy of complications. *Pediatrics*. 1975;55:342–347.
96. Fenner F, Henderson DA, Arita I, Jezek Z, Ladnyi ID. Developments in vaccination and control between 1900 and 1966. In: *Smallpox and Its Eradication*. Geneva, Switzerland: World Health Organization; 1988: Chap 7: 302–307.
97. Kempe CH. Studies on smallpox and complications of smallpox vaccination. *Pediatrics*. 1960;26:176–189.
98. Fulginiti VA, Winograd LA, Jackson M, Ellis P. Therapy of experimental vaccinal keratitis. *Arch Ophthalmol*. 1965;74:539–544.
99. Jack MD, Sorenson RW. Vaccinal keratitis treated with IDU. *Arch Ophthalmol*. 1963;69:730.

100. Redfield RR, Wright DC, James WD, Jones TS, Brown C, Burke DS. Disseminated vaccinia in a military recruit with human immunodeficiency virus (HIV) disease. *N Engl J Med*. 1987;316(11):673–676.
101. Guillaume JC, Saiag P, Wechsler J, Lesces MC, Roujeau JC. Vaccinia from recombinant virus expressing HIV genes. *Lancet*. 1991;377:1034–1035. Letter.
102. Goldstein JA, Neff JM, Lane JM, Koplan JP. Smallpox vaccination reactions, prophylaxis, and therapy of complications. *J Pediatr*. 1975; 55(3):342–347.
103. Centers for Disease Control. Adverse reactions to smallpox vaccination—1978. *MMWR*. 1978;28:265–267.
104. Lublin-Tannenbaum T, Katzenelson E, El-ad B, Katz E. Correlation between cutaneous reaction in vaccinees immunized against smallpox and antibody titer determined by plaque neutralization test and ELISA. *Viral Immunology*. 1990;3(1):19–25.
105. Hanna W. Studies in small-pox and vaccination. Bristol, England: Wright; 1913.
106. Dixon CW. *Smallpox*. London, England: Churchill; 1962.
107. Henderson DA. Smallpox. In: Sartwell PE, ed. *Preventive Medicine and Public Health by Maxcy-Rosenau*, 10th ed. New York: Appleton, Century-Crofts; 1973: 104–116.
108. Heering SL, Shohat T, Vonsover A, Mendelson E, Lerman Y. Neutralizing antibody titers following revaccination with vaccinia virus. *Public Health Rev*. 1990;18:94–97.
109. Mack TM, Noble J, Thomas DB. A prospective study of serum antibody and protection against smallpox. *Am J Trop Med Hyg*. 1972;21(2):214–218.
110. Sarkar JK, Mitra AC, Mukherjee MK. The minimum protective level of antibodies in smallpox. *Bull WHO*. 1975;52:307–311.
111. El-Ad B, Roth Y, Winder A, et al. The persistence of neutralizing antibodies after revaccination against smallpox. *J Infect Dis*. 1990;161:446–448.
112. Nyerges G, Hollós I, Losonczy G, Erdós L, Petrás G. Development of vaccination immunity in hospital personnel revaccinated at three-year intervals. *Acta Microbiol Acad Sci Hung*. 1972;19:63–68.
113. Centers for Disease Control. Vaccinia (smallpox) vaccine: Recommendations of the Immunization Practices Advisory Committee (ACIP). *MMWR*. 1991;40:1–10. Published erratum appears in *MMWR*. 1992;41(2):31.
114. Williams NR, Cooper BM. Counselling of workers handling vaccinia virus. *Occup Med*. 1993;43:125–127.
115. McIntosh K. Experience with the CV1 strain. In: Quinnan GV, ed. *Vaccinia Viruses as Vectors for Vaccine Antigens*. New York, NY: Elsevier; 1985: 91–100.
116. Cherry JD, Connor JD, McIntosh K, et al. Clinical and serologic study of four smallpox vaccines comparing variations of dose and routes of administration: Standard percutaneous revaccination of children who received primary subcutaneous vaccination. *J Infect Dis*. 1977;135:176–182.
117. Graham JS. Captain, Medical Corps, US Army. Personal communication, May 1995.
118. Guillaume JC, Saiag P, Wechsler L, Lescs MC, Roujeau RC. Vaccinia from recombinant virus expressing HIV Genes. *Lancet*. 1991;337:1034–1035.
119. Graham BS, Belshe RB, Clements ML, et al. Vaccination of vaccinia-naive adults with human immunodeficiency virus type 1 gp160 recombinant vaccinia virus in a blinded, controlled, randomized clinical trial. *J Infect Dis*. 1992;166:244–252.

120. Tartaglia J, Perkus ME, Taylor J, et al. NYVAC: A highly attenuated strain of vaccinia virus. *Virology*. 1992;188:217–232.
121. Kempe CH, Bowles C, Meiklejohn G, et al. The use of vaccinia hyperimmune gamma-globulin in the prophylaxis of smallpox. *Bull WHO*. 1961;25:41–48.
122. Heiner GG, Fatima N, Russell PK, et al. Field trials of methisazone as a prophylactic agent against smallpox. *Am J Epidemiol*. 1971;94(5):435–449.
123. Rao AR, Jacobs ES, Kamalakshi S, Bradbury, Swamy A. Chemoprophylaxis and chemotherapy in variola major, I: An assessment of CG662 and Marboran in prophylaxis of contacts of variola major. *Indian J Med Res*. 1969;57(3):477–483.
124. Bauer DJ, St Vincent L, Kempe CH, Downie AW. Prophylactic treatment of smallpox contacts with *N*-methylisatin-thiosemicarbazone (compound 33T57, Marboran). *Lancet*. 1963;2:494–496.
125. do Valle LAR, de Melo PR, de Salles Gomes LF, Proença LM. Methisazone in prevention of variola minor among contacts. *Lancet*. 1965;2:976–978.
126. Bauer DJ, St Vincent L, Kempe CH, Young PA, Downie AW. Prophylaxis of smallpox with methisazone. *Am J Epidemiol*. 1969;90:130–145.
127. Rao AR, McKendrick GDW, Velayudhan L, Kamalakshi K. Assessment of an isothiazole thiosemicarbazone in the prophylaxis of contacts of variola major. *Lancet*. 1966;1:1072–1074.
128. Rao AR, McFadzean JA, Kamalakshi K. An isothiazole thiosemicarbazone in the treatment of variola major in man. *Lancet*. 1966;1:1068–1072.
129. Bauer DJ. Thiosemicarbazones. In: Bauer DJ, ed. *Chemotherapy of Virus Diseases*. In: *International Encyclopaedia of Pharmacology and Therapeutics*. Vol 1, § 61. Oxford, England: Pergamon Press; 1972: 101–110.
130. Brainerd HD, Hanna L, Jawetz E. Methisazone in progressive vaccinia. *N Engl J Med*. 1967;276:620–622.
131. McLean DM. Methisazone therapy in pediatric vaccinia complications. *Ann N Y Acad Sci*. 1977;284:118–121.
132. Sodeik B, Griffiths G, Ericsson M, Moss B, Doms RW. Assembly of vaccinia virus: Effects of rifampin on the intracellular distribution of viral protein p65. *J Virol*. 1994;68(2):1103–1114.
133. Tseng CK, Marquez VE, Fuller RW, et al. Synthesis of 3-deazaneplanocin A, a powerful inhibitor of S-adenosylhomocysteine hydrolase with potent and selective in vitro and in vivo antiviral activities. *J Med Chem*. 1989;32(7):1442–1446.
134. Shuto S, Obara T, Toriya M, et al. New neplanocin analogues, I: Synthesis of 6'-modified neplanocin A derivatives as broad-spectrum antiviral agents. *J Med Chem*. 1992;35(2):324–331.
135. de Clercq E, Holy A, Rosenberg I. Efficacy of phosphonylmethoxyalkyl derivatives of adenine in experimental herpes simplex virus and vaccinia virus infections in vivo. *Antimicrob Agents Chemother*. 1989;33(2):185–191.
136. Monsur KA, Hossain MS, Huq F, Rahaman MM, Haque MQ. Treatment of variola major with cytosine arabinoside. *J Infect Dis*. 1975;131(1):40–43.
137. Koplan JP, Monsur KA, Foster SO, et al. Treatment of variola major with adenine arabinoside. *J Infect Dis*. 1975;131(1):34–39.