

Medical Management of Smallpox Patients and Vaccination Complications

Public health officials should be immediately notified of any suspected smallpox patient. Currently, there is no proven treatment for clinical smallpox (variola). Clinical trials conducted during the smallpox era that evaluated several antiviral compounds, including N-methylisatin β -thiosemicarbazone (Maboran), adenide arabinoside, cytosine arabinoside, and idoxiuridine, failed to demonstrate clinical efficacy for these compounds.

Evaluation of modern day antiviral compounds at CDC is ongoing. One current antiviral, cidofovir, has shown some in-vitro and in-vivo (animal studies) activity against orthopoxviruses. However, its effectiveness for treating clinical smallpox or vaccine adverse events is not known. This medication is labeled for the treatment of CMV retinitis and has been associated with renal failure. Were an outbreak of smallpox to occur, this medication would be made available through the CDC or NIH under an Investigation of a New Drug (IND) protocol for potential treatment of smallpox or vaccine adverse events.

Medical management of a patient with smallpox is mainly supportive and consists of: 1) isolation of the patient to prevent transmission of the smallpox (variola) virus to non-immune persons, 2) monitoring and maintaining fluid and electrolyte balance, 3) skin care, and 4) monitoring for and treatment of complications. In addition, unless the diagnosis of smallpox is laboratory confirmed, the patient should also receive smallpox vaccination if they will be isolated with other confirmed or suspected smallpox cases. Vaccination of suspected cases of smallpox is done to prevent the accidental transmission of smallpox virus to any suspected smallpox patients who have been misdiagnosed as smallpox cases.

Isolation

In a smallpox outbreak, isolation of confirmed or suspected smallpox patient(s) may be accomplished by several different methods depending upon certain circumstances (number of patients, severity of illness, availability of resources, etc). Ultimately, the goal of isolation is to prevent transmission of smallpox from an infectious patient (from the time the rash appears until all of the scabs have separated - about 3-4 weeks) to non-immune individuals while maintaining an appropriate care and comfort level for the patient. All potential methods of isolation must be considered with these goals in mind. Several potential methods for patient isolation are outlined below. **Medical personnel should consult with public health officials to determine the most appropriate method for isolation of a smallpox patient(s).**

Hospital isolation - If a confirmed or suspected smallpox patient(s) require hospital care, the following steps must be taken while the patient(s) are hospitalized:

1. Place the patient(s) under strict respiratory and contact isolation in a room with negative air pressure (and individual hepa-filtered ventilation exhaust if available). This

room should have private shower/bathroom facilities and not share ventilation with any other part of the hospital.

2. Protective clothing including: gowns, masks (properly fitted N95 respirator masks), gloves, protective eyewear, and surgical booties should be worn by unvaccinated personnel who enter and leave the isolation room. Recently successfully vaccinated personnel should exercise contact precautions (gowns, gloves, etc.) and should wear a surgical mask and eye protection as indicated for procedures where contact with body fluids may occur.
3. Removal and disposal of all protective clothing into biohazard waste disposal containers should be done before leaving the isolation room and re-entering other areas of the hospital.
4. All infectious waste and contaminated protective clothing should be disposed of or sterilized in an appropriate manner (incineration for disposable materials, autoclaving, ethylene oxide decontamination, or laundering in hot water and bleach for reusable equipment or clothing). **Public health officials should be consulted for specific waste disposal and decontamination guidelines.**
5. Personnel entering the isolation room or handling infectious waste or clinical specimens from the patient(s) should be vaccinated or have documented successful recent smallpox vaccinations (within 3 years). **Public health officials should be contacted for vaccination requests.**
6. Steps should be taken to confirm or rule-out the diagnosis of smallpox. **Public health officials should be consulted for assistance with the laboratory diagnosis.**

Non-hospital isolation – Public health officials should be consulted before non-hospital isolation is initiated. Confirmed or suspected smallpox patients which do not require hospital care may be isolated in non-hospital facilities that do not have shared ventilation systems with other facilities (see Guide C – Isolation and Quarantine Guidelines). These facilities should have appropriate climate control capabilities (heating/air conditioning), running water, and bathroom facilities. If suspected and confirmed smallpox patients are isolated together, all patients should receive smallpox vaccination to prevent accidental transmission due to misdiagnosis. **All persons entering these facilities must have documented successful recent smallpox vaccinations (within 3 years).**

Fluid and Electrolyte balance

During the vesicular and pustular stages of smallpox, patients may experience significant fluid losses and become hypovolemic or develop shock. Fluid loss can result from: 1) fever, 2) nausea and vomiting, 3) decreased fluid intake due to swallowing discomfort from pharyngeal lesions, 4) body fluid shifts from the vascular bed into the subcutaneous tissue, and 5) massive skin desquamation in patients with extensive confluent lesions. Electrolyte and protein loss may also occur in these patients. Fluid and electrolyte balance should be monitored in hospitalized patients with appropriate oral or intravenous correction of imbalances. Patients with less severe disease who do not require hospitalization should be encouraged to maintain good oral intake of fluids, educated on

the signs/symptoms of hypovolemia/dehydration, and counseled on when to seek medical attention if hypovolemia/dehydration occurs.

Skin Care

The skin should be kept clean and efforts should be made to avoid rupturing vesicles or pustules. No salves or ointments should be applied. In general, scab lesions should be allowed to heal and separate on their own. All scabs should separate by 3-4 weeks, however, lesions on the palms and soles may persist longer than 3-4 weeks unless artificially removed. Bacterial superinfection of lesions may occur (see Monitoring and Treatment of Complications) and should be treated with appropriate antibiotics.

Monitoring and Treatment of Complications

Several complications may occur during the course of a smallpox infection. These include: 1) hemorrhagic, 2) secondary bacterial infections, 3) corneal ulceration and/or keratitis, 4) arthritis or “osteomyelitis variolosa”, 5) respiratory, 6) encephalitis, 7) gastrointestinal, and 8) genitourinary. These complications and their treatment are described below.

Hemorrhagic - Minor hemorrhagic manifestations such as subconjunctival hemorrhages occur commonly in smallpox patients. If these subconjunctival hemorrhages are isolated and are not accompanied by evidence of a consumption coagulopathy or active bleeding (decreasing hemoglobin, hematocrit or platelets), no specific therapy is needed. However, if signs of more extensive hemorrhage are present (mucosal bleeding, bleeding into smallpox lesions, ecchymoses, hematemesis, hematuria etc.) the patient should be evaluated for disseminated intravascular coagulation (DIC) and treated appropriately. Hemorrhagic complications may indicate a more severe form of the disease called “hemorrhagic smallpox”, which has a poor prognosis. Also, because of a high, sustained viremia coupled with mucosal hemorrhaging during their course of illness, these patients are highly infectious.

Secondary bacterial infections – Bacterial superinfections can include abscesses of skin lesions, pneumonia, osteomyelitis, joint infections, and septicemia. Laboratory diagnostics (gram stain, culture, antibiotic susceptibility testing etc.) should be performed to help guide antibiotic therapy.

Corneal ulceration and/or keratitis – These complications occurred more frequently in hemorrhagic-type smallpox but were occasionally seen in the more typical ordinary-type smallpox. In one case series [Rao AR, Smallpox, Bombay, 1972, The Kothari Book Depot] corneal ulcers occurred in 1% of non-hemorrhagic type smallpox cases and keratitis occurred in about 0.25%. Corneal ulcerations can appear around the 2nd week of illness and begin at the corneal margins. Ulcers can heal rapidly, leaving a minor opacity, or on occasion, may cause severe corneal scarring. Keratitis and corneal ulceration was far more common in malnourished individuals. Topical idoxuridine has been used but its efficacy is undocumented.

Arthritis or “Osteomyelitis variolosa” – This complication occurred in approximately 1.7% of the cases in case series reviewed by Rao (see above). It usually occurred after the 15th day and was accompanied by a brief recurrence of fever during the scabbing stage. The elbow is the most commonly affected joint and symmetrical, bilateral involvement was frequently seen. This complication was most commonly due to viral infection of the metaphyses of growing bones. Most cases resolved without permanent deformity.

Respiratory –Viral bronchitis and pneumonitis can be common complications of severe smallpox and are considered part of the normal disease syndrome. Treatment is symptomatic with measures to treat hypoxemia with supplemental oxygen and/or intubation/ventilation as indicated. Secondary bacterial pneumonia can occur and should be treated with appropriate antibiotics as guided by laboratory diagnostics (gram stain, culture, antibiotic susceptibility testing, etc.). Pulmonary edema is common in the more severe forms of smallpox, hemorrhagic and flat-type, and should be treated with careful monitoring of oxygenation, fluid-status, and blood pressure with supplemental oxygen, and diuretics administered as needed. Patients with cough during the first week of disease may transmit disease more readily than patients without a cough as this is the period when oral secretions contain the largest amount of virus. Patients that developed a cough later in the course of disease (after day 10), when viral counts in secretions were lower, are not as infectious as those that develop coughs earlier.

Encephalitis – This complication occurred in about 1 out of every 500 cases of smallpox. It usually appeared between the 6th and 10th day of illness when the rash was still in the papular or vesicular stage. During the smallpox era, this complication was a minor contributor to the case-fatality rate of classical smallpox (variola major), the most common form of smallpox. Although sometimes slow, recovery was usually complete.

Gastrointestinal – Nausea and vomiting can occur in the earlier stages of smallpox, especially in the prodromal period before rash development and should be treated symptomatically. Diarrhea may occasionally occur in the prodromal period or in the 2nd week of illness and should also be treated symptomatically as needed. Acute dilation of the stomach occurred rarely and was more common in infants. In some severe cases of smallpox (especially flat-type), extensive viral infection of the intestinal mucosa occurred with sloughing of the mucosal membrane. Most of these cases were fatal.

Genitourinary system – Orchitis occurred in 0.1% of the Rao case series and is usually unilateral. Hematuria can be present in hemorrhagic type smallpox if bleeding into the pelvis of the kidney occurs.

Vaccination and Vaccination Adverse Events

Contraindications for Vaccination

In general, the risk of developing smallpox for face-to-face contacts to smallpox cases outweighs the risk of developing complications for those contacts with contraindications.

When the level of exposure risk is unclear, the decision to vaccinate should be made after careful assessment of the potential risks versus benefits of smallpox vaccination.

Household members of contacts with contraindications to vaccination should consider housing themselves separately from vaccinated household members until the vaccination site has healed to decrease the risk of contact transmission of virus.

Persons with certain medical conditions are known to have a higher risk of developing severe complications following vaccination with vaccinia vaccine (smallpox vaccine). These include:

1. Persons with diseases or conditions which cause immunodeficiency, such as HIV, AIDS, leukemia, lymphoma, generalized malignancy, agammaglobulinemia, or therapy with alkylating agents, antimetabolites, radiation, or immunosuppressive doses of corticosteroids.

A household member with an immunodeficiency disease or who is undergoing one of the therapies listed, who is exposed to a recently vaccinated household member, is at risk of developing a post-vaccine complication due to potential accidental inoculation with virus from the vaccination site of a vaccinated person.

2. Persons who have been diagnosed with eczema, even if the condition is mild or not presently active.

A household member who has eczema or a history of eczema who is exposed to a recently vaccinated household member, is also at higher risk for developing a post-vaccine complication due to potential accidental inoculation with virus from the vaccination site of the vaccinated person.

3. Women who are pregnant or who are planning to become pregnant within a month following vaccination.
4. Persons with other acute or chronic skin conditions such as atopic dermatitis, burns, impetigo, or varicella zoster (shingles) should not be vaccinated until the condition resolves.
5. Persons with serious, life-threatening allergies to the antibiotics polymyxin B, streptomycin, tetracycline, or neomycin.

Recognition of Expected Vaccine Reactions/Take

Successful vaccination, is normally associated with tenderness, redness, swelling, and a lesion at the vaccination site. Primary vaccination may also be associated with fever for a few days and enlarged, tender lymph nodes in the axilla of the

vaccinated arm. These symptoms are more common in persons receiving their first dose of vaccine (15-20%) than in persons being revaccinated (0-10%).

The clinical manifestations of vaccination with vaccinia virus are dependent upon the immune status of the vaccine recipient. Local reactions to vaccination may be classified as a major (primary) reaction or an equivocal reaction.

1. Primary (major) reaction – This reaction would be expected for persons receiving their first or primary smallpox vaccination or in persons who received a primary vaccination many years previously. The majority of the population today would fall within one of these two groups. The inoculation site becomes reddened and pruritic 3-4 days after vaccination. A vesicle surrounded by a red areola then forms which becomes umbilicated and then pustular by the 7th to 11th day after vaccination. The red areola has enlarged tremendously by this time. The pustule begins to dry, the redness subsides, and the lesion becomes crusted between the 2nd and 3rd week. By the end of the 3rd week, the scab falls off leaving a permanent scar that at first is pink in color but eventually becomes flesh-colored. (Fig. 1) At the end of the first week between the vesicular and pustular phases, there may be a variable amount of fever, malaise, and regional lymphadenitis. These symptoms usually subside within 1-2 days and are more likely to occur in older children and adults than in infants.

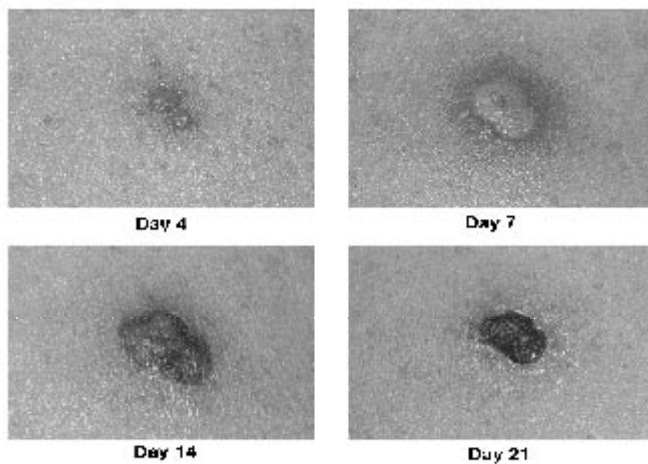


Fig. 1 – Major (primary) reaction - Expected local reaction after primary smallpox vaccination or revaccination after a prolonged period since primary vaccination using the multiple pressure technique.

2. Equivocal – All responses other than a major (primary) reaction are defined as equivocal reactions. These blunted reactions could be a result of a high level of immunity (i.e. a person who has received multiple previous smallpox vaccinations), or vaccination failure due to improper vaccine administration technique or less potent vaccine. If an equivocal reaction is observed, the

vaccination procedures should be checked and vaccination repeated with vaccine from another vial or vaccine lot as it would be difficult to determine if the blunted reaction was due to immunity or vaccine take failure.

Recognition of Adverse Reactions (AEs)

The overall risk of serious complications following vaccination with vaccinia vaccine is low. Complications occur more frequently in persons receiving their first dose of vaccine, and among young children (≤ 5 years of age). The most frequent complications of vaccination and their descriptions are listed below:

A. Inadvertent inoculation at other sites – This is the most frequent complication of vaccinia vaccination and accounts for about 50% of all complications following primary and re-vaccination. This complication occurs at a rate of about 1 in 2000 primary vaccinations and usually results from auto-inoculation when the virus is transferred by hand from the site of vaccination to other areas. The most common sites involved are the face, eyelid (Fig. 7), nose, mouth, genitalia, and rectum. Most lesions will heal without specific therapy, but Vaccinia Immune Globulin (VIG) may be useful for some cases of inadvertent ocular inoculation (see Indications and Guidelines for VIG Use below). VIG is contraindicated however, if vaccinia keratitis is present. Inadvertent inoculation can be prevented by handwashing after touching the vaccination site.

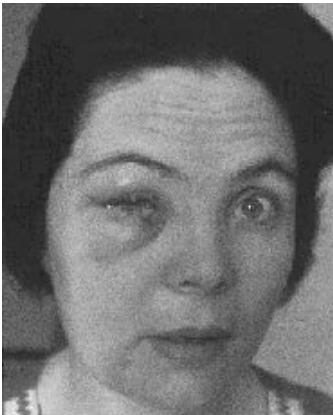

Fig. 7 – Inadvertent inoculation of lower eyelid [Fenner F, Henderson, DA, et al. Smallpox and its Eradication. WHO. 1988, Reprinted with permission of WHO]

B. Generalized vaccinia – This complication is characterized by a vesicular rash of varying extent resulting from blood-borne dissemination of vaccinia virus (Fig. 8). It is most frequently seen following primary vaccination and occurs at a rate of about 1 in 5000 vaccinations. Lesions occur between 6-9 days following vaccination and can be few or generalized. The rash of is generally self-limited in persons with no underlying illnesses (immune deficiencies) and usually requires no treatment with VIG except in patients who appear toxic or who have serious underlying conditions.